

Interactive CardioVascular and Thoracic Surgery

Surgical simulation – a new tool to evaluate surgical incisions in congenital heart disease?

Thomas Sangild Sørensen, Gerald Franz Greil, Ole Kromann Hansen and Jesper Mosegaard

Interact CardioVasc Thorac Surg 2006;5:536-539; originally published online Jun 29, 2006;

DOI: 10.1510/icvts.2006.132316

The online version of this article, along with updated information and services, is located on the World Wide Web at:

<http://icvts.ctsnetjournals.org/cgi/content/full/5/5/536>

Interactive Cardiovascular and Thoracic Surgery is the official journal of the European Association for Cardio-thoracic Surgery (EACTS) and the European Society for Cardiovascular Surgery (ESCVS). Copyright © 2006 by European Association for Cardio-thoracic Surgery. Print ISSN: 1569-9293.

Work in progress report - Congenital Surgical simulation – a new tool to evaluate surgical incisions in congenital heart disease?

Thomas Sangild Sørensen^{a,*}, Gerald Franz Greil^b, Ole Kromann Hansen^c, Jesper Mosegaard^d

^aCentre for Advanced Visualisation and Interaction, University of Aarhus, Aabogade 34, 8200 Aarhus N, Denmark

^bDepartment of Paediatric Cardiology, University of Tübingen, Germany

^cDepartment of Cardiothoracic and Vascular Surgery, Aarhus University Hospital, Denmark

^dDepartment of Computer Science, University of Aarhus, Denmark

Received 2 March 2006; received in revised form 5 June 2006; accepted 6 June 2006

Abstract

We introduce a new concept for preoperative planning and surgical education in congenital heart disease: surgical simulation. Recent advances in three-dimensional image acquisition have provided a new means to virtually reconstruct accurate morphological models while computer visualisation hardware now allows simulation of elastic tissue deformations interactively. Incision simulation is performed in two patients with complex congenital heart disease to preoperatively evaluate potential corrective surgical strategies. The relevant cardiac morphology was correctly depicted by the virtual models on which arbitrary incisions could be performed. By visualising the morphology in respect to each incision, different surgical strategies could be evaluated pre-operatively. We have taken the first step towards a clinically useful incision simulator for procedures in congenital heart disease and made an initial evaluation. With further developments it is likely that new tools for patient-specific preoperative planning and surgical training will emerge based on the presented ideas.

© 2006 Published by European Association for Cardio-Thoracic Surgery. All rights reserved.

Keywords: Surgical simulation; Surgical training; Congenital heart disease

1. Introduction

Recent advances in high-resolution, three-dimensional magnetic resonance imaging (3D MRI) have provided a new means to virtually reconstruct the morphology of the heart. Consequently, accurate reconstructions of both the intra-cardiac and the extracardiac morphology can be integrated in the preoperative planning process [1–3]. To take realism one step further, this paper presents our first experiences using a real-time surgical simulator for incision planning in relation to congenital heart disease. In this initial work we investigate two hypotheses, namely that (1) patient-specific incision planning using deformable virtual models of the individual morphology can be used to preoperatively determine which incisions provide the best access to access a given defect, and (2) on a generalised virtual model containing any desired ventricular- and/or atrial septal defects, incision simulation can be used as an educational tool to illustrate various incision strategies to access these defects.

2. Materials and methods

To study our first hypothesis, incision simulation was performed to evaluate potential corrective strategies for two patients clinically referred for three-dimensional MRI

[4]. Patient 1 was a 10-year-old girl born with double outlet right ventricle, the great arteries side-by-side with the aorta to the right, and a sub-pulmonary VSD. An intra-ventricular baffle was inserted for a biventricular repair. Two baffle leakages remained following this procedure and the intra-ventricular tunnel appeared restrictive. Patient 2 was a 5-year-old boy with a univentricular heart (dextrocardia, hypoplastic right ventricle, discordant ventriculo-arterial connections, and left pulmonary artery stenosis). Following three Fontan operations resulting in total cavopulmonary connection (TCPC), he was examined for a possibly restrictive VSD. To examine our second hypothesis we obtained a configurable model of several atrial- and ventricular septal defects from a virtual reconstruction of an adult volunteer's normal heart in which the defects were added by hand.

3D MRI was performed on an Intera 1.5T scanner (Philips Medical Systems, Best, Netherlands) using an isotropic steady state free precession acquisition protocol under general anaesthesia with respiration gated to a 5-mm window on the right hemi-diaphragm [4]. Images were obtained with a resolution of 1.75³ mm³ and acquired in end-diastole. From each MRI dataset we reconstructed a virtual model of the myocardium and vessel borders using the 'Virtual Reality Heart' software (Systematic Software Engineering, Denmark) and custom software. The elastic properties of the modelled tissue were obtained as described in [5–7]. Two-handed interaction was achieved

*Corresponding author. Tel.: +45 8942 5647; fax: +45 8942 5601.

E-mail address: sangild@cavi.dk (T.S. Sørensen).



Fig. 1. Surgical simulation. Two Phantom Omnis (Sensable Technologies, USA) are used for free-hand interaction with force feedback. Cutting and tissue manipulation can be performed interactively.

by two Phantom Omnis (Sensable Technologies, USA) providing the exact three-dimensional position and orientation of each hand (Fig. 1). In addition, each of these devices was programmed with force feedback giving the user the sensation of being able to touch the surface and feel the magnitude of the forces applied during the procedures [8].

The study was approved by the institutional ethics committee on human research.

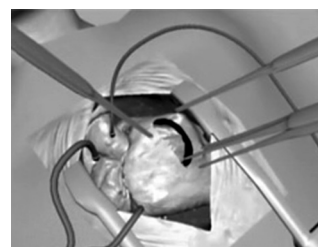
3. Results

The 3D MRI acquisitions were completed successfully in less than 10 min each. Unfortunately, segmentation of the myocardium was quite time consuming and required about 10 h of work for each of the two dataset: Identifying the blood pool in the images, and hence determining the endocardium and blood pool border was easily achieved, but identifying the epicardium border was much harder and ended up taking practically all the segmentation effort. Vessel walls were automatically ‘grown’ from the endoluminal borders. In the dataset from the volunteer the septal defects were added manually requiring just a few additional minutes of work.

Arbitrary incisions could be made in the models and the bordering tissue pulled aside to provide realistic views of the intra-cardiac morphology. A movie (Video 1) showing the running simulator is available as online supplementary material.

Fig. 2 shows two incisions in the virtual reconstruction of patient 1. In Fig. 2a an incision at the aortic root was made to visualise the interior baffle pathway (white circle). From this view it is clear that the narrow baffle is restrictive. Fig. 2b shows an incision at the root of the main pulmonary artery revealing the exact location of the larger of the two ventricular septal defects (circle in insert). This location allows closure either by surgery or by catheterisation. The ideal surgical access to the encircled VSD (Fig. 2b) was clearly demonstrated in the incision simulator.

Fig. 3 shows two incisions in patient 2. Fig. 3a shows an initial approach: an incision at the aortic root (viewed from above). The simulator reveals, however, that the location



Video 1. A virtual heart model was reconstructed from three-dimensional MRI in a volunteer. A ventricular septal defect was manually introduced in the model before importing it into the real-time surgical incision simulator presented in this paper. The video shows the interactive making of a trans-ventricular and a trans-atrial incision in order to investigate the access to the septal defect by the respective surgical approaches.

of the VSD (white circle) would be difficult to reach from this incision due to its distance. Fortunately the simulator allows us to rethink and redo the incision. By moving it slightly downwards as shown in Fig. 3b, the VSD is now more directly accessible (white circle). Very importantly, the course of the coronary arteries is also visible and avoided by the current incision. Based on the available imaging information, it was decided that surgery to enlarge the VSD is necessary. Of the two surgical strategies illustrated in Fig. 3, the incision shown in Fig. 3b is the most promising and has been recommended.

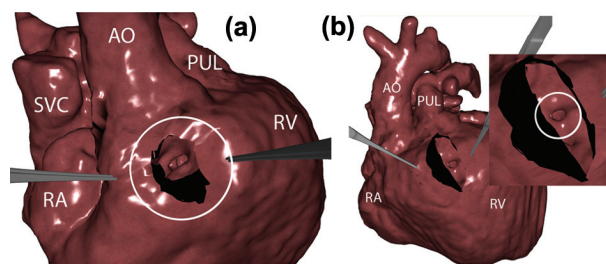


Fig. 2. Incision simulation in patient 1. (a) An incision has been made at the aortic root (in the right ventricle) showing a narrow intraventricular pathway (circle). The tips of two surgical tools that keep the incision open can be seen. (b) An incision at the pulmonary root shows the position of a ventricular septal defect (circle in enlargement). RA: right atrium, RV: right ventricle, AO: aorta, PUL: main pulmonary artery, SVC: superior vena cava.

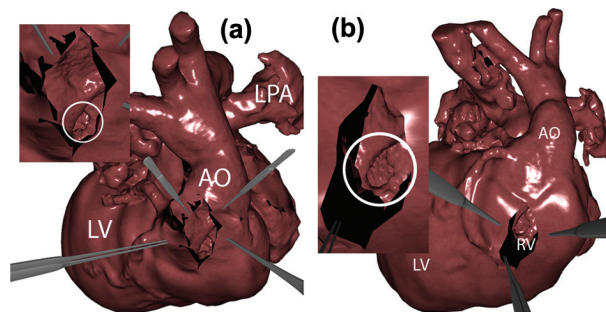


Fig. 3. Incision simulation in patient 2. (a) Viewed from above, an initial incision at the aortic root reveals a restrictive but hard-to-access ventricular septal defect (circle in enlargement). (b) From an anterior view, a second incision makes the VSD more easily accessible (circle in enlargement). AO: aorta, RV: right ventricle, LV: left ventricle, LPA: left pulmonary artery.

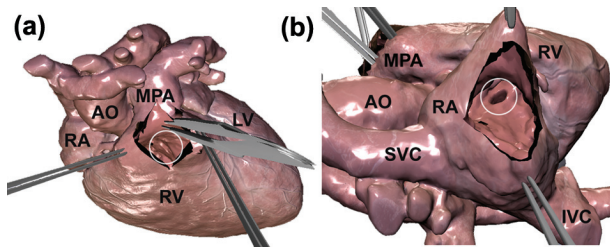


Fig. 4. Incision simulation as an educational tool. A muscular ventricular septal defect (circles) is accessed by a trans-ventricular incision (a) and a trans-atrial incision (b). RA: right atrium, RV: right ventricle, LV: left ventricle, AO: aorta, MPA: main pulmonary artery, IVC: inferior vena cava, SVC: superior vena cava.

Fig. 4 shows a trans-ventricular incision (a) and a trans-atrial incision (b) to reveal a mid-muscular VSD that was manually introduced in the 3D MRI of a volunteer. Fig. 4a shows an incision at the root of the main pulmonary artery perpendicular to the acute marginal branches of the right coronary artery and the left anterior ascending coronary artery. The muscular VSD is revealed (white circle) by the central instrument. The access to this VSD by a trans-atrial approach is shown in Fig. 4b. The initial incision is visible at the top-left part of the subfigure.

4. Discussion

For many years preoperative planning in congenital heart disease has relied on the abilities of surgeons to convert two-dimensional imaging information to three-dimensional mental models and surgical strategies. Virtual reconstructions were recently introduced as a new supplementary tool to assist in this process, giving a three-dimensional overview of the morphology [1,2]. This paper advances this work by providing an interactive setup that offers surgeons an opportunity to make arbitrary incisions on elastic virtual models giving realistic surgical views of the intracardiac morphology preoperatively. A superior spatial understanding of potential surgical incisions in relation to individual morphology is obtained as the simulator lets the user examine morphological details and incisions from any desired angle.

In patient number 1 we used this tool to visualise a restrictive intraventricular baffle and an associated VSD. The information provided by this representation of the intracardiac morphology has been an important factor in the currently ongoing decision-making for the patient. In patient number 2 we visualised a restrictive VSD through two slightly different incisions. Due to the risks of impairing right ventricular function associated to an extended ventriculotomy, the initial incision was placed right at the aortic root. It turned out, however, that it would be hard to reach the VSD through this incision (Fig. 3a). Consequently, a new incision was made which provided better access to the defect (Fig. 3b). The incision simulator again provided important preoperative information on how to proceed with the actual surgery. Similar experiences regarding the surgical approach of this type of defect have previously been reported [9]. Based on this discussion we approve our first hypothesis, that patient-specific incision simulation as pre-

sented in this paper can indeed be used to determine which incisions provide the best access to given septal defects.

In Fig. 4 we used the simulator with a slightly different purpose, namely to generally illustrate the access to a septal defect by two different incisions. We specifically demonstrated the access to a ventricular septal defect by a trans-ventricular and a trans-atrial approach. As the defect was created manually in the model reconstruction process, we could easily have chosen to visualise any imaginable ventricular- or atrial septal defect instead. Subsequently we could have made any desired incision, e.g. a transatrial incision, a right or left ventriculotomy, or an apical infundibulotomy in our search to locate the defect [9–13]. We could even make incisions which in real-life would have severe functional consequences. We believe that the freedom in the points we are able to teach using an interactive incision simulator makes it a promising new educational tool to illustrate various incision strategies to access septal defects. By this discussion we approve our second hypothesis.

We are currently using the tools described in ref. [1] to segment the 3D MRI and reconstruct the morphological models. This is currently a time consuming process as the software was designed to rapidly identify the blood pool but not the myocardium. We are consequently continuing our research in segmentation algorithms to better detect the epicardium border. In combination with a '3D sculpturing tool' in preparation we optimistically expect to be able to create patient-specific models suitable for incision simulation in just an hour or two in the near future – provided a good quality 3D MRI is available.

Speculating on the basis of future improvements to the simulator, the advantages of surgical simulation are (at least) two-fold. Firstly, we can illustrate various elements of surgical procedures, and secondly, we can allow surgeons to rehearse these elements virtually. The incision planning tool we presented in this paper is the first step on a long road. When support for suturing and handling of patches is added, we could potentially rehearse complex or rare surgical procedures (e.g. a double outlet right ventricle repair or a Mustard operation) in a virtual environment. In Figs. 2–4 there was no constraints on the angles and positions from which the heart could be examined and accessed. In future scenarios, the natural limitations caused by the positioning in the thorax needs to be addressed in order to achieve a realistic training scenario. One step in this direction is shown in the supplementary online movie and in Fig. 1, in which a model of the thorax was included in the graphics.

The education of young surgeons relies on a master/apprentice relationship and follows the 'see one, do one, teach one' principle in broad terms. We believe that in the foreseeable future, surgical simulators will become important tools to aid in these transitions. They could provide numerous training scenarios with an unlimited number of trials that will allow young surgeons to experiment and learn from their mistakes. Eventually, these surgeons will be better prepared for their upcoming work in the operating theatre. Fully developed surgical simulators also hold the potential to increase the cost-effectiveness of surgical training. The time used for training could become shorter

since particular and even rare cases could be performed repeatedly without any preparation. Furthermore, optimally prepared procedures are likely to minimise the costs of follow-up treatments.

Acknowledgements

Our research is funded by the Danish Research Council (grant #2059-03-0004), the Danish Heart Foundation (grant #05-10-B359-A657-22265), the 'EHLKE' foundation, and the 'Stiftung zur Förderung der Erforschung von Zivilisationserkrankungen', Baden-Baden, Germany. Furthermore, we would like to acknowledge Professor Ludger Sieverding, Dept. Cardiology, University of Tübingen, Germany, and Professor Vibeke Hjortdal, Dept. Cardiothoracic and Vascular Surgery, University of Aarhus, Denmark for their valuable feedback.

References

- [1] Sorensen TS, Pedersen EM, Hansen OK, Sorensen K. Visualization of morphological details in congenitally malformed hearts: virtual three-dimensional reconstruction from magnetic resonance imaging. *Cardiol Young* 2003 October;13:451–460.
- [2] Razavi RS, Hill DL, Muthurangu V, Miquel ME, Taylor AM, Kozerke S, Baker EJ. Three-dimensional magnetic resonance imaging of congenital cardiac anomalies. *Cardiol Young* 2003 October;13:461–465.
- [3] Hemminger BM, Molina PL, Egan TM, Detterbeck FC, Muller KE, Coffey CS, Lee JK. Assessment of real-time 3D visualization for cardiothoracic diagnostic evaluation and surgery planning. *J Digit Imaging* 2005 April 19.
- [4] Sorensen TS, Korperich H, Greil GF, Eichhorn J, Barth P, Meyer H, Pedersen EM, Beerbaum P. Operator-independent isotropic three-dimensional magnetic resonance imaging for morphology in congenital heart disease: a validation study. *Circulation* 2004 July 13;110:163–169.
- [5] Sorensen TS, Mosegaard J. An introduction to GPU accelerated surgical simulation. 3rd Symposium on Biomedical Simulation. Zurich, Switzerland. *Lecture Notes in Computer Science (4072)* 2006;93–104.
- [6] Mosegaard J, Herborg P, Sorensen TS. A GPU Accelerated Spring Mass System for Surgical Simulation. *Stud Health Technol Inform* 2005; 111:342–348.
- [7] Mosegaard J, Sorensen TS. Real-time Deformation of Detailed Geometry Based on Mappings to a Less Detailed Physical Simulation on the GPU. *Immersive Projection Technology and Eurographics Virtual Environments (IPT & EGVE) Workshop* 2005;105–110.
- [8] Sorensen TS, Mosegaard J. Haptic feedback for the GPU-based surgical simulator. *Stud Health Technol Inform* 2005;119:523–528.
- [9] Stellin G, Padalino M, Milanese O, Rubino M, Casarotto D, Van PR, Van PS. Surgical closure of apical ventricular septal defects through a right ventricular apical infundibulotomy. *Ann Thorac Surg* 2000 February;69:597–601.
- [10] Alexiou C, Chen Q, Galogavrou M, Gnanapragasam J, Salmon AP, Keeton BR, Haw MP, Monro JL. Repair of tetralogy of Fallot in infancy with a transventricular or a transatrial approach. *Eur J Cardiothorac Surg* 2002 August;22:174–183.
- [11] Van PS, Mayer JE Jr., Berman NB, Flanagan MF, Geva T, Van PR. Apical ventricular septal defects: follow-up concerning anatomic and surgical considerations. *Ann Thorac Surg* 2002 January;73:48–56.
- [12] Myhre U, Duncan BW, Mee RB, Joshi R, Seshadri SG, Herrera-Verdugo O, Rosenthal GL. Apical right ventriculotomy for closure of apical ventricular septal defects. *Ann Thorac Surg* 2004 July;78:204–208.
- [13] Tsang VT, Hsia TY, Yates RW, Anderson RH. Surgical repair of supposedly multiple defects within the apical part of the muscular ventricular septum. *Ann Thorac Surg* 2002 January;73:58–62.

Surgical simulation – a new tool to evaluate surgical incisions in congenital heart disease?

Thomas Sangild Sørensen, Gerald Franz Greil, Ole Kromann Hansen and Jesper Mosegaard
Interact CardioVasc Thorac Surg 2006;5:536-539; originally published online Jun 29, 2006;

DOI: 10.1510/icvts.2006.132316

This information is current as of September 19, 2006

Updated Information & Services	including high-resolution figures, can be found at: http://icvts.ctsnetjournals.org/cgi/content/full/5/5/536
Supplementary Material	Supplementary material can be found at: http://icvts.ctsnetjournals.org/cgi/content/full/icvts.2006.132316/DC1
References	This article cites 10 articles, 6 of which you can access for free at: http://icvts.ctsnetjournals.org/cgi/content/full/5/5/536#BIBL
Subspecialty Collections	This article, along with others on similar topics, appears in the following collection(s): Cardiac - other http://icvts.ctsnetjournals.org/cgi/collection/cardiac_other Congenital - acyanotic http://icvts.ctsnetjournals.org/cgi/collection/congenital_acyanotic Congenital - cyanotic http://icvts.ctsnetjournals.org/cgi/collection/congenital_cyanotic
Permissions & Licensing	Requests to reproducing this article in parts (figures, tables) or in its entirety should be submitted to: icvts@ejcts.ch
Reprints	For information about ordering reprints, please email: icvts@ejcts.ch

Interactive CardioVascular and Thoracic Surgery